

A fresh approach for varicose veins

A new form of sclerotherapy uses ultrasound guidance, as Mr Philip Coleridge Smith explains

Sclerotherapy is an especially useful technique for the common problem of varicose veins because it avoids a surgical procedure.

The problem with normal sclerotherapy is that it treats the superficial varices adequately, but does not address the cause of varices — incompetence of the saphenous veins.

Ultrasound-guided foam sclerotherapy is a technique that aims to obliterate all saphenous trunks, perforating veins and visible varices.

Colour duplex ultrasound imaging identifies which veins are causing the visible varices, usually the great or small saphenous veins, and sometimes perforating veins as well.

Under ultrasound control, injections of sclerosant foam are placed in the saphenous veins and all varices.

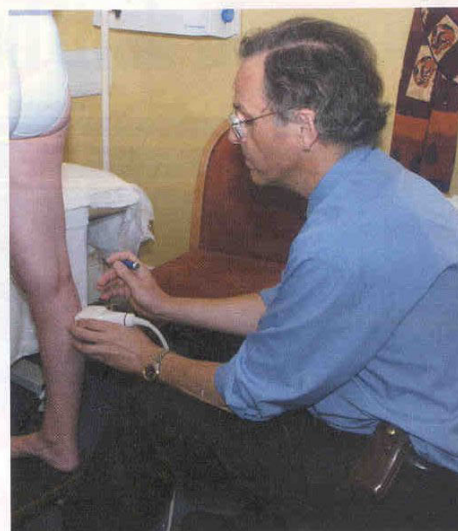
Sodium tetradecyl is used to create the foam, a product used for sclerotherapy in the UK for the past 50 years.

Its use as a foam was originally described in 1950, but its true value was not realised until

ultrasound imaging became widely used in the management of venous disease.

The sodium tetradecyl is mixed vigorously with air to produce the foam, which is much more effective than a liquid sclerosant because it displaces the blood on entering the vein, and is therefore more active on the vascular lining.

The foam disintegrates within a few minutes and becomes plasma protein bound in an



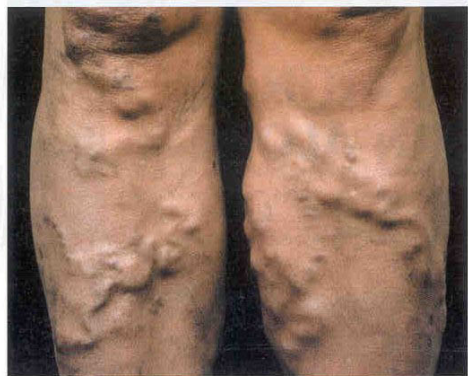Ultrasound-guided imaging identifies which veins are affected

inactive state. The air partially dissolves in the blood and partially travels as bubbles to the lungs. The bubbles are so small that they cannot cause a clinical problem.

Air embolism has not been reported as a complication in the literature. Large volumes of air (200–300ml) have to be injected rapidly in order to cause a clinically significant air embolism.

About 20ml of foam can be injected in small quantities over a period of 20 to 30 minutes, at a maximum of 10ml at one time.

In liquid form, no more than 4ml of sclerosant can be injected at any one treatment session, and this would only treat a few varices. But as a foam, this amount is sufficient to manage the whole of an incompetent



Visible varices can be treated effectively using foam sclerotherapy

Key facts on foam sclerotherapy

- Varicose veins are a common problem. venous system, and is done as an outpatient procedure.
- Ultrasound-guided foam sclerotherapy is a technique that aims to obliterate all saphenous trunks, perforating veins and visible varices.
- There is no need for general anaesthesia.
- Under ultrasound control, injections of sclerosant foam are placed in the saphenous veins and all varices.
- The treatment takes about 30 minutes and most patients can return to work immediately afterwards, if consistent with wearing compression bandages.
- The treatment is performed by a vascular surgeon or specialist with experience in ultrasonography of the
- Two sessions are required to treat one leg and three sessions for both legs.
- This technique may be used in primary, recurrent or secondary varicose veins.

Mr Philip Coleridge Smith DM FRCS
Consultant Vascular Surgeon
The Middlesex Hospital, Mortimer Street, London W1

For correspondence:
 Thames Valley Nuffield Hospital
 Wexham Street
 Wexham, Bucks SL3 6NB
 Tel: 0870 609 2389

The London Vein Institute
 4 Upper Wimpole Street
 London W1G 6LF
 Tel: 020 7323 2830

www.bvi.uk.com
enquiries@bvi.uk.com

saphenous vein and associated varices, so minimising the total amount of sclerosant used.

The number of injections needed generally is also reduced, and this also leads to less sclerosant being injected.

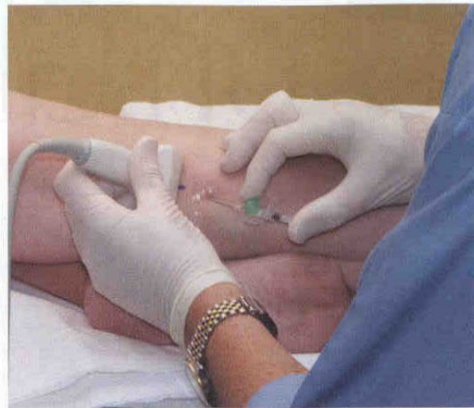An outpatient procedure

The treatment is performed by a vascular surgeon or specialist with experience in ultrasonography of the venous system, and is done as an outpatient procedure.

There is no need for general anaesthesia, and it can be done in a consulting room.

The patient lies supine on an examination couch. This encourages the veins to empty, and also avoids the risk of fainting. A local anaesthetic injection is given into the skin, and an intravenous cannula is inser-

Ultrasound-guided foam sclerotherapy has been successfully used on hundreds of thousands of patients



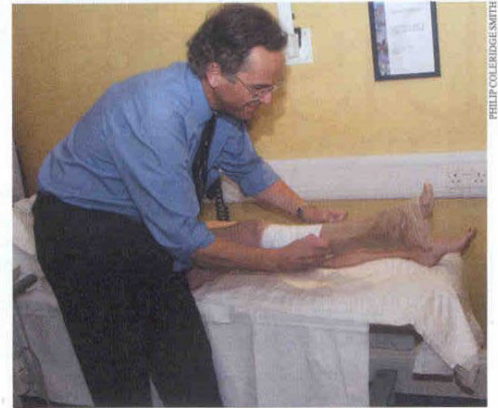
About 20ml of foam can be injected over a period of 20 to 30 minutes

ted into the saphenous vein under ultrasound control.

During the injection of foam into the larger saphenous trunks, the limb is elevated to

empty the veins and facilitate the sclerosis of varicose veins.

Superficial varices can be injected with a 23g or 30g fine needle.



A compression bandage should be applied at the end of the treatment

At the end of treatment a firm compression bandage is applied to the limb. This and compression stockings are worn for two weeks after treatment.

The treatment takes about 30 minutes, including the bandaging of the legs.

The foam injections cause no pain or discomfort, and most patients can return to work immediately afterwards, if this is consistent with wearing compression bandages.

In general, two sessions are required to treat one leg and three sessions for two. It costs £800 to treat one leg and £1,300 for both legs, but this includes several sessions and follow-up consultations.

Most patients can benefit

Most patients with varicose veins can be managed in this way. I now treat 90 per cent of my patients using this method.

This technique may be used in primary, recurrent or secondary varicose veins arising from incompetence of the great or small saphenous vein or from perforating vein incompetence. It is most suitable for patients with small or medium-sized varices.

Surgical treatment is reserved for patients with extensive large varicose veins where foam sclerotherapy may take several sessions to obtain a good outcome.

A small number of patients with leg ulcers attributable to great saphenous vein incompetence have been treated.

The technique is also useful in weaker patients because general anaesthesia is avoided, as well as in those who do not wish to have an operation.

A recent joint publication from the US and New Zealand reported that 95 per cent of treated saphenous veins remain obliterated after three years, as demonstrated by duplex ultrasonography.

In contrast, recently published surgical series report clinical recurrence of varicose veins in 40 per cent of limbs after five years, with demonstrable recurrence shown by ultrasound imaging in 23 per cent after three years.

Few side-effects

Side-effects are few. The most frequent problems arise from thrombophlebitis, but this may follow any type of sclerotherapy. This is managed by compression, analgesia and needle aspiration of thrombus, which usually resolves the problem quickly.

Some brown discolouration may occur with superficial vein injection, and a lump may be felt by the patient. These problems usually resolve spontaneously over several months.

Ultrasound-guided foam sclerotherapy has been used successfully worldwide. In the UK, NHS consultants in Yeovil, Chester, Newcastle, Nottingham, Birmingham, Cambridge and London use this technique.

NICE is developing guidelines that should encourage its more widespread adoption. They are expected to be published this summer.

● *Mr Coleridge Smith is director of The Middlesex Hospital Vascular Laboratory, and reader in surgery at the department of surgery, UCL Medical School, London*

GP

Further reading

- Barrett J M, Allen B et al. Microfoam ultrasound-guided sclerotherapy of varicose veins in 100 legs. *Dermatol Surg* 2004; 30: 6-12
- Belcaro G, Cesarone M R, Di Renzo A, et al. Foam-sclerotherapy, surgery, sclerotherapy, and combined treatment for varicose veins: a 10-year prospective, randomized, controlled trial (VEDICO Trial). *Angiology* 2003; 54: 307-15.

- NICE Interventional procedure consultation document: Ultrasound-guided Foam Sclerotherapy for Varicose Veins